

# Dexmedetomidine versus propofol on the sedation of pediatric patients during magnetic resonance imaging (MRI) scanning: a meta-analysis of current studies

Qiang Zhou<sup>1,\*</sup>, Lingli Shen<sup>2,\*</sup>, Xinxian Zhang<sup>1</sup>, Jiong Li<sup>1</sup> and Yong Tang<sup>1</sup>

<sup>1</sup>Department of Radiology, XuZhou Children's Hospital, Xuzhou, Jiangsu 221006, China

<sup>2</sup>Department of Neurology, The Tenth Ward, XuZhou Children's Hospital, Xuzhou, Jiangsu 221006, China

\*These authors contributed equally to this study

**Correspondence to:** Xinxian Zhang, **email:** zxx\_858@sina.com

**Keywords:** magnetic resonance imaging, dexmedetomidine, propofol, sedation, meta-analysis

**Received:** June 22, 2017

**Accepted:** September 18, 2017

**Published:** November 01, 2017

**Copyright:** Zhou et al. This is an open-access article distributed under the terms of the Creative Commons Attribution License 3.0 (CC BY 3.0), which permits unrestricted use, distribution, and reproduction in any medium, provided the original author and source are credited.

## ABSTRACT

**Magnetic resonance imaging (MRI) is a widely applied diagnostic approach for detection of pediatric diseases. Sedatives are commonly used to acquire the accurate MRI images. Dexmedetomidine and propofol serve as sole or combined sedatives in pediatric MRI scanning. This meta-analysis aimed to compare the efficacy of dexmedetomidine and propofol in children undergoing MRI. Pubmed, Cochrane Library and Web of Science were searched up to June, 2017. Onset of sedation time, recovery time, sedation time, MRI time, MRI quality and emergence delirium were analyzed. 6 studies with 368 subjects were enrolled in this meta-analysis. The pooling data showed that propofol had a shorter onset of sedation time (WMD: 6.05, 95% CI: 3.12 – 8.98,  $P < 0.0001$ ) and recovery time (WMD: 1.01, 95% CI: 0.36–1.67,  $P < 0.001$ ) than dexmedetomidine. But for sedation time and MRI scanning time, there were no differences between the two groups (sedation time:  $P = 0.29$ ; MRI scanning time:  $P = 0.50$ ). There were no significance between dexmedetomidine and propofol on MRI quality (MRI quality 1:  $P = 1.00$ ; MRI quality 2:  $P = 0.68$ ; MRI quality 3:  $P = 0.45$ ). Two studies using Pediatric Anesthesia Emergence Delirium (PAED) to assess emergence delirium 10 minutes after awakening showed that propofol had a lower PAED than dexmedetomidine (WMD: 2.57, 95% CI: 0.15–5.00,  $P = 0.04$ ). Thus, propofol should be encouraged in pediatric patients undergoing MRI for its better sedative effects and a low incidence of emergence delirium.**

## INTRODUCTION

Magnetic resonance imaging (MRI) has become a widely applied diagnostic tool for a series of pediatric diseases [1–3]. This non-invasive, accurate but time-consuming diagnostic approach requires the pediatric examinees to fully cooperate without motion during the operation [4]. Then sedation is usually necessary to accomplish it. Multiple sedative drug regimens have been adopted to achieve satisfactory sedation level. Among them, dexmedetomidine and propofol are commonly used in clinical practice for their specific efficacy and safety characteristics [5, 6]. Both of them have a short sedation and recovery time. Emergence delirium is a common

complication in clinical observation [7]. Although several studies have compared the two drugs in pediatric patients undergoing MRI in terms of the above items. A meta-analysis was needed to evaluate the effects of dexmedetomidine and propofol in pediatric MRI imaging.

## RESULTS

### Flow of the included studies

As shown in Figure 1, 96 potential studies were found through searching. Then after careful and thorough screening of the abstracts and whole texts, 36 duplicates, 13 reviews, 2 conference poster were excluded. 38 articles

didn't compare the effects between dexmedetomidine and propofol, or provide the data that we want. 1 article was retracted by the journal. They were also excluded. Therefore, 6 studies [8–13] were included with a total of 368 patients fulfilling the inclusion criteria.

### Study characteristics and quality assessment

The articles included were published from 2006 to 2017. 3 were from USA, and the rest 3 came from Turkey, Singapore and India, respectively. There were 186 and 182 patients in dexmedetomidine and propofol, respectively. 1 study used functional MRI, and 5 studies applied MRI scanning. Two studies assessed the sedation level with Ramsay sedation scale, but the other studies didn't indicated it. The baseline characteristics were displayed in Table 1, including age, weight, sex and sedation protocols.

### Meta-analysis outcomes

The sedation effects, including onset of sedation time, recovery time, discharge time, MRI scanning time were displayed in Supplementary Table 1. The pooling data showed that propofol had a shorter onset of sedation time (WMD: 6.05, 95% CI: 3.12–8.98,  $P < 0.0001$ ) (Figure 2) and recovery time (WMD: 1.01, 95% CI: 0.36–1.67,  $P < 0.001$ ) (Figure 3) than dexmedetomidine (Table 2). But for sedation time and MRI scanning time, there were no differences between the two groups (sedation time:  $P = 0.29$ ; MRI scanning time:  $P = 0.50$ ) (Table 2) (Supplementary Figures 1 and 2). As shown in Supplementary Table 2, 2 studies assessed MRI image quality using a three-point scale (1 = no motion; 2 = minor movement; 3 = major movement necessitating another scan). The pooling analysis showed that there were no

significance between dexmedetomidine and propofol (MRI quality 1:  $P = 1.00$ ; MRI quality 2:  $P = 0.68$ ; MRI quality 3:  $P = 0.45$ ) (Table 2) (Supplementary Figures 3, 4 and 5). Two studies assessing Pediatric Anesthesia Emergence Delirium (PAED) 10 minutes after awakening showed that propofol had a lower PAED than dexmedetomidine (WMD: 2.57, 95% CI: 0.15–5.00,  $P = 0.04$ ) (Table 2) (Figure 4) (Supplementary Table 3).

### Heterogeneity and bias

Sensitivity analysis was made in comparison with significant heterogeneity among studies (Table 2). There were less than 10 high-quality studies in our meta-analysis, a publication bias assessment cannot be performed accurately.

## DISCUSSION

This meta-analysis compared the effects of dexmedetomidine and propofol among pediatric patients undergoing MRI using the available medical data. The study discovered some findings: there is enough evidence in support of the clinical application of propofol for a shorter onset of sedation time and recovery time than dexmedetomidine. No significance were found between the two interventions of sedation time, MRI scanning time and MRI image quality. Propofol seemed to have a lower rate of emergence delirium.

We were fully aware of a previously published meta-analysis [14] in 2015 on the same subject. However, we found that one article included in that study was retracted, making their findings not reliable. This then encouraged the establishment of this meta-analysis. The present study is of great importance to demonstrate the

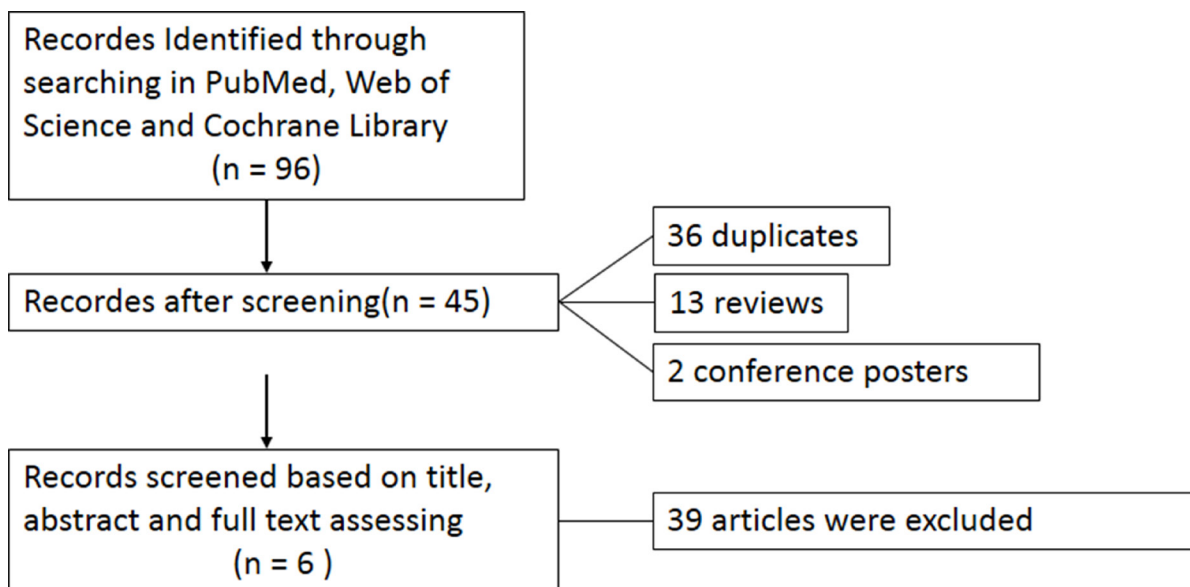


Figure 1: Flow diagram of the meta-analysis.

**Table 1: The baseline characteristics of the included studies**

Dexmedetomidine							
Year	Author	Age	Weight	Sex	Intervention	No.	
2006	Koroglu	4 ± 1.88	14 ± 4.14	17	1 ug/kg initial dose followed by continuous infusion of 0.5 ug/kg/h	30	
2012	Bernal	6	NA	14	continuous infusion of mean dose 1.8 ug/kg/h	24	
2014	Wu	-	-	-	2 ug/kg followed by continuous infusion of 2 ug/kg/h	46	
2015	Bong	3	14	24	a single dose of 0.3 ug/kg	40	
2016	Watt	4.6 ± 0.8	16.8 ± 5.0	13	1 ug/kg followed by 1 ug/kg/h infusion	16	
2017	Kamal	5.2 ± 2.69	16.41 ± 6.21	12	2 ug/kg for 10min followed by continous infusion of 1 ug/kg/h	30	
Propofol							
		Age	Weight	Sex	Intervention	No.	
		3 ± 2.03	14 ± 4.57	10	3 mg/kg initial dose followed by a continuous infusion of 100 ug/kg/min	30	
		6.16	NA	9	continuous infusion of mean dose 97.9 ug/kg/h	19	
		-	-	-	2 mg/kg and followed by continuous infusion of 200 ug/kg/min	49	
		4	15.2	24	a single dose of 1 mg/kg	39	
		5.1 ± 1.1	18.2 ± 4.1	10	infusion at 300 ug/kg/min for 10 mins and reduced to 250 ug/kg/min	15	
		4.15 ± 2.32	14.86 ± 5.49	14	1 mg/kg bolus followed by continuous infusion of 100 ug/kg/min	30	

NA, Not applicable.

comparison of dexmedetomidine and propofol sedation in children undergoing MRI. Although the conclusions of the two are quite similar, it is vital to take the current analysis to exclude the potential discrepancy caused by the retracted study. This would help the purity and accuracy of understanding of dexmedetomidine and propofol.

MRI scanning is a useful diagnostic imaging tool in pediatric patients for its high accuracy and non-radiation

[15]. However, it requires the examinees' full cooperation to be motionless. It is difficult for pediatric sufferers to follow the instructions during scanning, making the examination hard to finish [16]. Therefore, anesthesiologists and other clinical operators are encouraged to use specific sedatives in practice. Dexmedetomidine and propofol are both commonly used sedatives in children undergoing MRI examination for their efficacy and safety [5, 17].

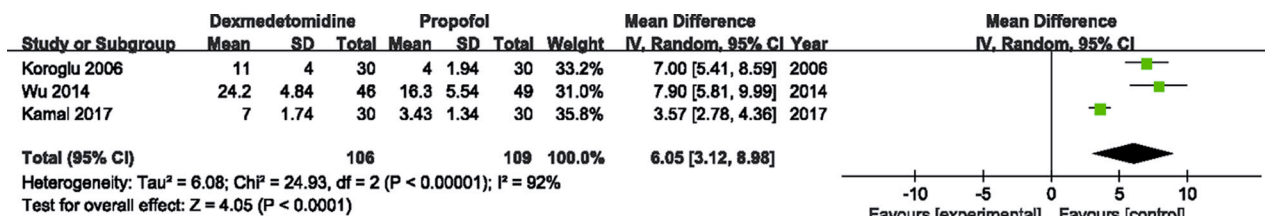


Figure 2: Forest plot and meta-analysis of sedation time.

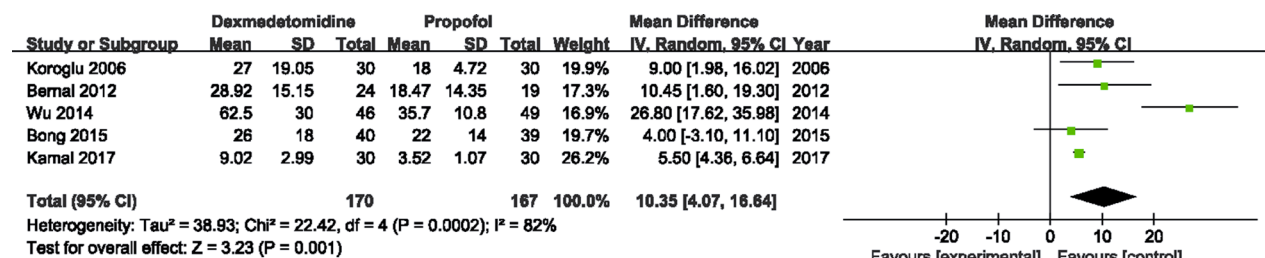


Figure 3: Forest plot and meta-analysis of recovery time.

**Table 2: Meta-analysis of the included studies**

	Study No.	WMD (95% CI)	P	Study Heterogeneity			
				$\chi^2$	df	I <sup>2</sup> , %	P
Onset of sedation							
time	3	6.05 (3.12, 8.98)	< 0.0001	24.93	2	92	< 0.00001
Recovery time	5	10.35 (4.07, 16.64)	0.001	22.42	4	82	0.0002
Sedation time	4	2.15 (-1.82, 6.12)	0.29	4.00	3	25	0.26
MRI time	3	-1.37 (-5.38, 2.64)	0.50	6.95	3	57	0.07
<b>MRI quality</b>							
1	2	1.00 (0.47, 2.12)	1.00	0.15	1	0	0.70
2	2	-0.03 (-0.19, 0.13)	0.68	0.00	1	0	1.00
3	2	1.80 (0.39, 8.32)	0.45	NA	NA	NA	NA
PAED	2	2.57 (0.15, 5.00)	0.04	6.27	1	84	0.01

MRI, Magnetic resonance imaging; PAED, Pediatric Anesthesia Emergence Delirium; WMD, weighted mean difference.

Dexmedetomidine is a potent  $\alpha_2$ -adrenoceptor agonist. It has sedative, analgesic and opioid-sparing effects and is suitable for short- and long-term sedation. It's used in pediatric patients due to its efficacy and lack of adverse respiratory events [18, 19]. Propofol is an intravenous agent used for induction and maintenance of anesthesia in children. It has many pharmacological advantages over other agents such as rapid effect, short action and few side effects through the interaction with various neurotransmitter receptors [6, 20]. Several studies had evaluated and compared them in pediatric subjects during MRI in recent years. Koroglu et al. [6, 20] believed that dexmedetomidine and propofol produced enough sedation in children undergoing MRI. And dexmedetomidine would be a reliable alternative to propofol for its less side effect incidences. Also no significance were found between the two of adverse events by Bernal et al. [9]. However, that study was done using functional MRI, which might be a factor for the results. And it didn't compare the two on sedative effects. Some researchers discovered a quite different fact in clinical application. Propofol yielded overall better outcomes than dexmedetomidine in terms of timeliness [10].

Emergence delirium is a common and well-recognized complication occurring in children with general anesthesia [7]. In addition, the incidence of this complication is relatively high following pediatric sedation for MRI. PAED scale is developed to quantify it by assessing restlessness, eye contact, inconsolability, purpose

actions and consciousness [21]. Both dexmedetomidine and propofol are capable of reducing emergence delirium in the practice [22–24]. Bong et al. compared the two sedatives and found that there were no differences of the two on the incidence of emergence delirium [22–24]. In this study, two studies investigated PAED scores 10 minutes after awakening. Consistent with the previous studies, no differences were found after pooling analysis.

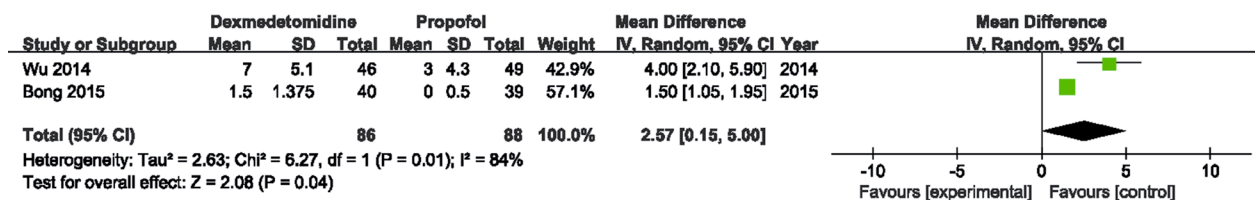
There were some limitations in this study. First, the limited number of studies included in this meta-analysis would hinder the application of our conclusion. Second, the sedation procedure of each drug in all the included studies were not the same. This might cause heterogeneity. Third, we could not thoroughly examine physiological parameter changes during scanning for the lack of the relevant data. Further analysis on this topic should be done in the future. This will facilitate the clinical selection of the suitable sedative drug to avoid potential unexpected effects.

We believe that propofol should be encouraged in pediatric patients undergoing MRI for its better sedative effects and a low incidence of emergence delirium.

## MATERIALS AND METHODS

### Literature search strategy

Preferred Reporting Items for Systematic Reviews and Meta-analysis (PRISMA) [25] and Meta-



**Figure 4: Forest plot and meta-analysis of PAED.** PAED, Pediatric Anesthesia Emergence Delirium.



analysis of Observational Studies in Epidemiology [26] recommendations were used for study reporting. This study was based on previously studies; thus, ethical approval and patient consent were not required. A computerized search of the Pubmed, Web of Science, and Cochrane Library databases was performed through to June 2017, without restriction on the language or publication type, using keywords as following: pediatric, child, children, adolescence, adolescent, nuclear resonance imaging, magnetic resonance imaging, MRI, dexmedetomidine, Precedex, Dexmedetomidine Hydrochloride, Propofol, Diprivan and Disoprofol.

### Inclusion criteria and exclusion criteria

In order to insure the homogeneity of the studies, the following criteria should be met: (1) all the patients were  $\leq 18$  years old, and scheduled to accomplish MRI with general anesthesia; (2) the study used dexmedetomidine and propofol as the sole sedative agent and compared the two in the sedation process; (3) the information, including onset of sedation time, recovery time, sedation time, MRI scanning time, MRI quality assessment and adverse effects were provided. Also the exclusion criteria was given as following: (1) patients were accompanied with developmental delay, cognitive decline, severe central nervous system disorders that might influence the anesthesia effects; (2) studies used dexmedetomidine or propofol plus other sedative reagents for anesthesia. Any disagreement over the selection process was resolved after consensus-based discussion.

### Data extraction and quality assessment

Data from the included studies were extracted and summarized independently by Qiang Zhou and Lingli Shen. Any disagreement was resolved by consensus-based discussion and determined by Xinxian Zhang. The outcomes were the comparison of sedation effects (onset of sedation time, recovery time and sedation time), MRI scanning quality (MRI time and MRI image quality) and the incidence of emergence delirium PAED score 10 minutes after awakening) between dexmedetomidine and propofol. The quality of cohort studies was assessed by the Cohort Studies Version of Newcastle-Ottawa Quality Assessment Scale, which consists of three factors: Patient selection, comparability of the study groups, and assessment of outcome. A score of 0–9 was allocated to each study. Studies that achieved six or more stars were considered to be of high quality.

### Statistical analysis

Meta-analysis was performed on studies that provided data on outcomes of patients using the software package Stata 14. The weighted mean difference (WMD) was used to compare continuous variables. All

results were reported with 95% confidence intervals (CIs). Statistical heterogeneity was assessed using the  $I^2$  statistic, which describes the proportion of total variation that is attributable to differences among trials rather than sampling error (chance). An  $I^2$  value of  $< 25\%$  was defined to represent low heterogeneity, a value between 25% and 50% was defined as moderate heterogeneity and  $> 50\%$  was defined as high heterogeneity. The random-effects model was used if there was high heterogeneity between studies. Otherwise, the fixed-effects model was used. Publication bias was calculated using Egger's test.

### CONFLICTS OF INTEREST

The authors report no conflicts of interest.

### REFERENCES

1. Callen DJ, Shroff MM, Branson HM, Lotze T, Li DK, Stephens D, Banwell BL. MRI in the diagnosis of pediatric multiple sclerosis. *Neurology*. 2009; 72:961–967.
2. Moore MM, Gustas CN, Choudhary AK, Methratta ST, Hulse MA, Geeting G, Egli KD, Boal DK. MRI for clinically suspected pediatric appendicitis: an implemented program. *Pediatr Radiol*. 2012; 42:1056–1063.
3. DeBella K, Poskitt K, Szudek J, Friedman JM. Use of “unidentified bright objects” on MRI for diagnosis of neurofibromatosis 1 in children. *Neurology*. 2000; 54:1646–1651.
4. Arthurs OJ, Sury M. Anaesthesia or sedation for paediatric MRI: advantages and disadvantages. *Curr Opin Anaesthesiol*. 2013; 26:489–494.
5. Siddappa R, Riggins J, Kariyanna S, Calkins P, Rotta AT. High-dose dexmedetomidine sedation for pediatric MRI. *Paediatr Anaesth*. 2011; 21:153–158.
6. Chidambaran V, Costandi A, D’Mello A. Propofol: a review of its role in pediatric anesthesia and sedation. *Cns Drugs*. 2015; 29:543–563.
7. Moore AD, Anghelescu DL. Emergence Delirium in Pediatric Anesthesia. *Paediatr Drugs*. 2017; 19:11–20.
8. Koroglu A, Demirbilek S, Teksan H, Sagir O, But AK, Ersoy MO. Sedative, haemodynamic and respiratory effects of dexmedetomidine in children undergoing magnetic resonance imaging examination: preliminary results. *Brit J Anaesth*. 2005; 94:821–824.
9. Bernal B, Grossman S, Gonzalez R, Altman N. FMRI under sedation: what is the best choice in children? *J Clin Med Res*. 2012; 4:363–370.
10. Wu J, Mahmoud M, Schmitt M, Hossain M, Kurth D. Comparison of propofol and dexmedetomidine techniques in children undergoing magnetic resonance imaging. *Pediatric anesthesia*. 2014; 24:813–818.
11. Bong CL, Lim E, Allen JC, Choo WLH, Siow YN, Teo PBY, Tan JSK. A comparison of single-dose dexmedetomidine or

- propofol on the incidence of emergence delirium in children undergoing general anaesthesia for magnetic resonance imaging. *Anaesthesia*. 2015; 70:393–399.
12. Watt S, Sabouri S, Hegazy R, Gupta P, Heard C. Does dexmedetomidine cause less airway collapse than propofol when used for deep sedation? *J Clin Anesth*. 2016; 35:259–267.
  13. Kamal K, Asthana U, Bansal T, Dureja J, Ahlawat G, Kapoor S. Evaluation of efficacy of dexmedetomidine versus propofol for sedation in children undergoing magnetic resonance imaging. *Saudi journal of anaesthesia*. 2017; 11:163–168.
  14. Fang H, Yang L, Wang X, Zhu H. Clinical efficacy of dexmedetomidine versus propofol in children undergoing magnetic resonance imaging: a meta-analysis. *Int J Clin Exp Med*. 2015; 8:11881–11889.
  15. Tzaribachev N, Well C, Schedel J, Horgler M. Whole-body MRI: a helpful diagnostic tool for juvenile dermatomyositis case report and review of the literature. *Rheumatol Int*. 2009; 29:1511–1514.
  16. Kawana S. [Recent advances in pediatric anesthesia]. *Masui*. 2010; 59 Suppl:S108–S118. [Article in Japanese].
  17. Usher AG, Kearney RA, Tsui BC. Propofol total intravenous anesthesia for MRI in children. *Paediatr Anaesth*. 2005; 15:23–28.
  18. Weerink MA, Struys MM, Hannivoort LN, Barends CR, Absalom AR, Colin P. Clinical Pharmacokinetics and Pharmacodynamics of Dexmedetomidine. *Clin Pharmacokinet*. 2017; 56:893–913.
  19. Venkatraman R, Hungerford JL, Hall MW, Moore-Clingenpeel M, Tobias JD. Dexmedetomidine for Sedation During Noninvasive Ventilation in Pediatric Patients. *Pediatr Crit Care Med*. 2017. <https://doi.org/10.1097/PCC.0000000000001226>.
  20. Kang H, Kim DK, Choi YS, Yoo YC, Chung HS. Practice guidelines for propofol sedation by non-anesthesiologists: the Korean Society of Anesthesiologists Task Force recommendations on propofol sedation. *Korean J Anesthesiol*. 2016; 69:545–554.
  21. Sikich N, Lerman J. Development and psychometric evaluation of the pediatric anesthesia emergence delirium scale. *Anesthesiology*. 2004; 100:1138–1145.
  22. Ali MA, Abdellatif AA. Prevention of sevoflurane related emergence agitation in children undergoing adenotonsillectomy: A comparison of dexmedetomidine and propofol. *Saudi J Anaesth*. 2013; 7:296–300.
  23. Shukry M, Clyde MC, Kalarickal PL, Ramadhyani U. Does dexmedetomidine prevent emergence delirium in children after sevoflurane-based general anesthesia? *Paediatr Anaesth*. 2005; 15:1098–1104.
  24. Aouad MT, Yazbeck-Karam VG, Nasr VG, El-Khatib MF, Kanazi GE, Bleik JH. A single dose of propofol at the end of surgery for the prevention of emergence agitation in children undergoing strabismus surgery during sevoflurane anesthesia. *Anesthesiology*. 2007; 107:733–738.
  25. Panic N, Leoncini E, de Belvis G, Ricciardi W, Boccia S. Evaluation of the endorsement of the preferred reporting items for systematic reviews and meta-analysis (PRISMA) statement on the quality of published systematic review and meta-analyses. *PLoS One*. 2013; 8:e83138.
  26. Stroup DF, Berlin JA, Morton SC, Olkin I, Williamson GD, Rennie D, Moher D, Becker BJ, Sipe TA, Thacker SB. Meta-analysis of observational studies in epidemiology: a proposal for reporting. Meta-analysis Of Observational Studies in Epidemiology (MOOSE) group. *JAMA*. 2000; 283:2008–2012.